

OLYMPUS


True to Life

Olympus Business

Our Purpose

Making people's lives healthier, safer and more fulfilling

Our Core Values



Introduction

Olympus developed the world's first practical gastroscope in 1950. This innovation played a pivotal role in establishing methods for the early diagnosis of stomach cancer, a disease that had long been one of the leading causes of death in Japan. Since then, Olympus has contributed to drive the evolution of endoscopy.

Advancements in minimally invasive treatments are continuously being made within the medical field. Olympus offers comprehensive products and solutions for treating various diseases—not only in gastroenterology, but also in urology, respiratory, etc. These innovations help enhance patient care, improve quality of life (QOL) and lower medical costs by shortening hospital stays and enabling faster recovery.

Through the publication of “Olympus Business,” we aim to provide our stakeholders with a clear overview of our key business areas. This report also highlights recent trends and advancements in our medical devices for both diagnosis and treatment of various diseases.

Investor Relations, Olympus Corporation

Contents

- 02 Business Area: Gastrointestinal (GI)
- 03 Main Diseases, Procedures, and Products in GI
- 11 Structure and Components of GI Endoscopy System
- 12 Business Areas: Urology, Respiratory, Surgical
- 13 Main Diseases, Procedures, and Products in Urology
- 15 Main Diseases, Procedures, and Products in Respiratory
- 17 Structure of Surgical Endoscopy System and Surgical Energy Devices

Forward-Looking Statements

This material contains forward-looking statements that reflect management's current views, plans, and expectations based on information available at the time of preparation. These forward-looking statements are not guarantees of future performance and involve known and unknown risks, uncertainties, future business decisions, and other internal and external factors that may cause the Company's actual results, performance, achievements, or financial position to be materially different from any future results expressed or implied by these forward-looking statements.

About Products

Some products in this material have not yet been released in some regions.

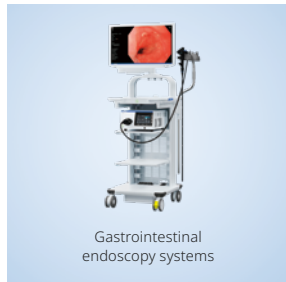GI Endoscopy

The GI endoscope is inserted into the digestive organs through natural orifices (mouth, nose and anus) for observation, diagnosis, staging, and treatment of benign and malignant diseases.

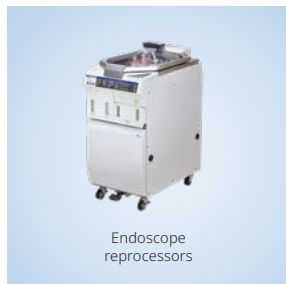GI EndoTherapy

Miniaturized catheter-based devices that can be inserted into the working channel of flexible endoscopes and used to accomplish various diagnostic and therapeutic interventions (tissue sampling, stenting, anastomosis, and hemostasis)

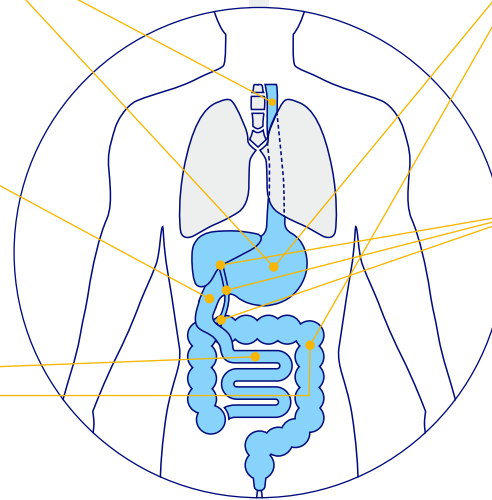

Gastrointestinal endoscopy systems



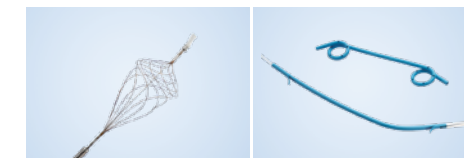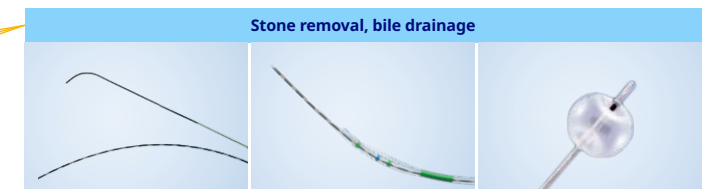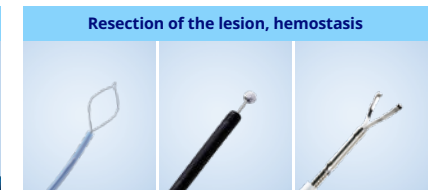
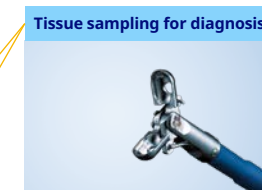Reprocessing



Flexible endoscopes



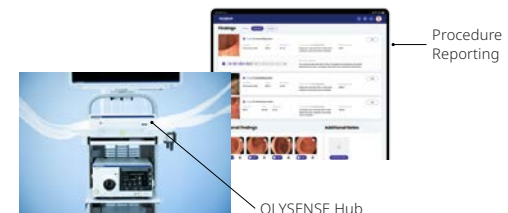Endotherapy devices



OLYSENSE*, Intelligent Endoscopy Ecosystem

OLYSENSE is the core of the Olympus Intelligent Endoscopy Ecosystem. It is an AI-powered digital health platform that integrates with hospital systems to strengthen clinical outcomes, improve quality, and streamline operational workflows.

*OLYSENSE is a trademark of Olympus Corporation and/or its affiliated entities. All trademarks, logos and brand names are the property of their respective owners.

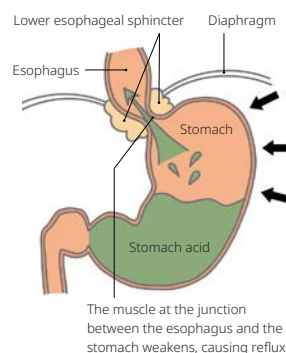


Esophagus

> Gastroesophageal Reflux Disease (GERD)

The condition in which stomach contents containing a large volume of gastric acid flow back into the esophagus is called Gastroesophageal Reflux Disease (GERD). This occurs when gastric acid refluxes into the esophagus, irritating its mucosa. GERD is classified into two categories: reflux esophagitis and Non-Erosive Reflux Disease (NERD), based on symptoms and the condition of the esophageal mucosa.

Reflux esophagitis is characterized by symptoms such as heartburn and acid reflux, and endoscopy reveals abnormal lesions, including erosion and ulcers on the esophageal mucosa. In contrast, NERD also presents with symptoms like heartburn and acid reflux; however, endoscopy shows no mucosal lesions such as erosion or ulcers.



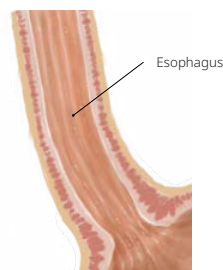Source: "Onaka-Kenka.com" (Japanese only)
<https://www.onaka-kenka.com/>

> Barrett's Esophagus

The esophageal mucosa is lined with squamous epithelium, whereas the stomach and colon are lined with columnar epithelium. Barrett's esophagus is a condition in which the mucosa in the lower esophagus is continuously replaced with columnar epithelium from the mucosa of the stomach. Repeated inflammation of the esophageal mucosa caused by gastric acid reflux can lead to cellular degeneration.

> Esophageal Cancer

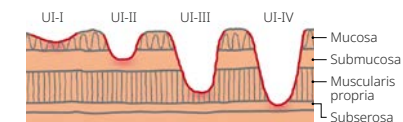
The walls of the esophagus are made from multiple layers of mucosa and muscle. Cancer of the esophagus typically occurs in the innermost mucosa. This is called "squamous cell carcinoma" and over 90% of Japanese people with cancer of the esophagus have this type of cancer. Habitual drinking and smoking are sources of risk. There is another type of esophageal cancer called "adenocarcinoma" which is more common in Europe and the U.S. This type of cancer is found in 60-70% of esophageal cancer cases in Europe and the U.S. Barrett's esophagus, where stomach acid flows up the esophagus and causes inflammation of the esophageal mucosa, is thought to be associated with adenocarcinoma.



Stomach

> Stomach Ulcers

An ulcer is a condition in which the gastric mucosa is damaged, extending into the muscular layer beneath the mucosa. It occurs due to the digestive action of gastric acid on the body's own mucosa. Gastric ulcers are classified as acute or chronic. Acute gastric ulcers are shallow, irregular ulcers with several areas of erosion, whereas chronic gastric ulcers are typically round and occur as single ulcers.

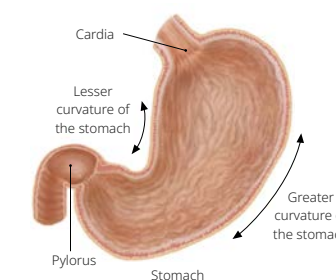


UI-I : Erosion with loss of mucosal surface
 UI-II : Ulceration tissue with loss as far as the submucosa
 UI-III : Ulceration tissue with loss as far as the muscularis propria
 UI-IV : Ulceration tissue with loss extending past the muscularis propria

Source: "Onaka-Kenka.com" (Japanese only)
<https://www.onaka-kenka.com/>

> Stomach Cancer

It is thought to arise in the mucosae of the stomach from gastritis and atrophy. When atrophy occurs in the mucosae of the stomach, it leads to atrophic gastritis, which can lead to "intestinal metaplasia," a condition in which the stomach-type mucosa turns into intestinal-type mucosa. Intestinal metaplasia is known to develop into cancer. Recently it has been shown that this is related to the bacterium *Helicobacter pylori*. *H. pylori* causes inflammation of the mucosa in the stomach and has been observed to lead to atrophic gastritis and intestinal metaplasia.

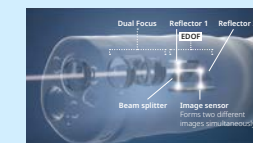


Gastrointestinal Scope

Gastrointestinal videoscopes are for viewing the stomach and duodenum through the esophagus and usually have an insertion tube length of 1,030mm. Videoscopes have a forward-facing lens on the distal tip which is ideal for observing tissue directly in front of the endoscope. Videoscopes designed to be inserted through the mouth typically have an insertion tube diameter of around 10mm; videoscopes designed for passage through the nose are about half that diameter. There are various types of scopes, and one of them is a videoscope featuring Extended Depth of Field (EDOF)*1 technology. Even in situations where a large or raised lesion is being diagnosed with an endoscope and keeping the entire lesion in focus is difficult, scopes with EDOF technology*2 allow physicians to obtain sharp, in-focus images, supporting highly accurate endoscopy.



Gastrointestinal videoscope



Click here to see more details about EDOF. [\[Link\]](#)

*1 EDOF technology creates an image in total focus by using two prisms to split light entering the endoscope lens into two separate beams with near- and far-focused images. Those beams are then projected simultaneously onto an image sensor, combining them into one image with a wide depth of field.

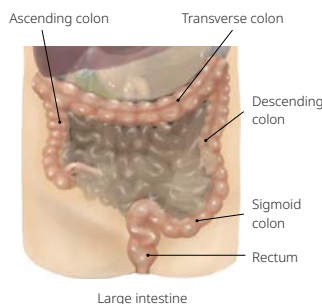
*2 A colonoscope is also included in the product lineup.

Colon

> Colorectal Cancer

Cancer of the large intestine includes both colon cancer and rectal cancer, but colon cancer especially is increasing rapidly. Consuming animal fats causes greater secretion of biliary acid to help with digestion. There are carcinogens among the substances that develop when digesting fats. It is believed that cancer occurs in the mucosa of the large intestine.

The inside of the large intestine consists of four layers. Sometimes, benign polyps called adenomas occur in the mucosa. Many cases of colorectal cancer are believed to be related to these polyps. Furthermore, it has been recently discovered that there are also flat and depressed cancers that develop directly from the mucosa. The most common areas for colorectal cancer are the rectum and sigmoid colon, which cancers account for about 70% of all cases.



> Benign Polyp

A tissue that protrudes from the mucous membrane of the colon is called a colon polyp. The polyp has a high probability of occurring in the rectum or the sigmoid colon, and its size is between a few millimeters and 3cm. They are largely divided into neoplastic and non-neoplastic polyps. Small polyps are generally asymptomatic, but if they become large, symptoms such as fecal occult blood and fresh blood in the stool can occur.

> Inflammatory Bowel Disease (IBD)

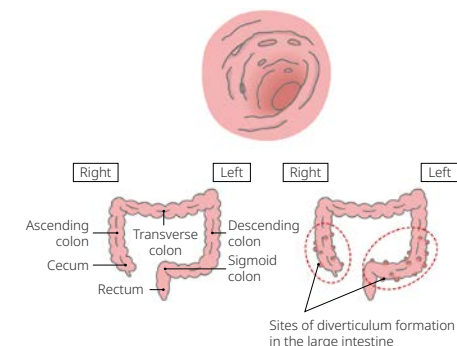
It is a disease characterized by inflammation of the gastrointestinal mucosa, primarily affecting the intestines. Broadly, it is classified into ulcerative colitis (UC) and Crohn's disease (CD). Ulcerative colitis is an inflammatory condition of the colon that mainly involves the mucosa and submucosa, leading to erosions and ulcer formation. Although it primarily affects the colon and is associated with persistent diarrhea and recurrent bloody stools, it may involve the immune system and is considered a systemic disease. Crohn's disease is an inflammatory bowel disease of unknown etiology. Symptoms vary depending on the location of inflammation and ulceration; however, patients often present with abdominal pain, diarrhea, anal pain, anal fistulas, and fever.

*Williet, N., Tournier, Q., et al. Effect of Endocuff-assisted colonoscopy on adenoma detection rate: meta-analysis of randomized controlled trials. *Endoscopy*, 50 (9), 846-860. Doi:10.1055/a0577-3500. Available at: <https://www.ncbi.nlm.nih.gov/pubmed/29698990>.

> Diverticulosis

Diverticulosis is a condition in which 5–10mm bulging pouches (diverticula) form in the walls of the colon. Most diverticula are around 1cm in size, but larger ones can have openings exceeding 2cm. Diverticula develop due to increased intestinal pressure from congenital or acquired factors, with insufficient dietary fiber intake being a major acquired cause.

Diverticulosis is usually asymptomatic but can lead to acute complications such as diverticular hemorrhage, where blood vessels within the diverticula rupture and bleed, and diverticulitis, in which bacteria within the diverticula cause infection.



Source: "Onaka-Kenko.com" (Japanese only)
<https://www.onaka-kenko.com/>

Colonoscope

Colonoscopes are longer than gastrointestinal videoscopes in order to accommodate the long 1.5m length of the adult colon. Standard-length colonoscopes are 1,330mm long. Extended length models are 1,680mm long. The colonoscope has a forward-facing tip. In order to facilitate insertability into the colon a flexibility adjustment ring allows the operator to adjust the stiffness of the insertion section during the procedure. Colonoscopes typically have an insertion tube diameter of around 13mm.



Colonoscope

ENDOCUFF VISION, Colonoscope Distal Attachment

This device is attached to the colonoscope's distal end to support visualization in procedures such as colonoscopy screening and polyp removal. ENDOCUFF VISION features a proprietary design comprised of a flexible arm with extensions placed on the device circumference. The arms open the colon's bended section and mucosal folds, providing a clearer view inside the colon and making it easier to detect polyps and adenomas. Research* shows that compared with standard colonoscopies, those performed using this technology increase the adenoma detection rate (ADR) by up to 11%. According to this research, each 1% improvement in the ADR lowers the risk of colon cancer by 3%.



ENDOCUFF VISION

Small Bowel

> Gastrointestinal Bleeding

Gastrointestinal bleeding is suspected when symptoms such as melena or bloody stools indicate bleeding in the digestive tract, but the source cannot be identified through either upper gastrointestinal endoscopy or colonoscopy. Although causes other than small bowel lesions are possible, most cases involve bleeding from the small bowel.


There are many diseases that can cause small bowel bleeding. Conditions such as Crohn's disease, intestinal Behçet's disease, and NSAID-induced enteritis are inflammatory disorders of the small intestine. In addition, small bowel tumors such as malignant lymphoma and gastrointestinal stromal tumors (GIST), as well as arteriovenous malformations and small bowel diverticula, can also be causes of small bowel bleeding.

Small Bowel Enteroscope

This involves using an endoscope with a balloon attached on the distal end such that the inflated balloon holds the intestine open and allows the endoscope to be moved forward. Insertion can be via either the mouth or anus. As the instrument channel outlet is also provided, as on a conventional endoscope, it can be used for biopsies or to perform simple procedures. To be long enough to view the small intestine, the endoscope has a length of 2,000mm and a diameter of approximately 9mm.



Small intestinal videoscope



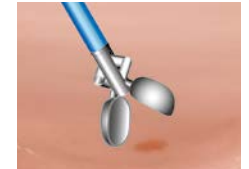Single balloon enteroscope

Digestive Tract (Esophagus/Stomach/Colon/Small Bowel)

Main diagnostic method

Biopsy

A biopsy is a diagnostic procedure that removes pieces of tissue which is suspected of being a lesion, subject to pathological testing under a microscope.



Biopsy

Main endotherapy device used

Biopsy Forceps

Biopsy forceps include the standard type and also a type with a needle which prevents slipping on the surface of mucosa. Various biopsy forceps are used such as a single-side opening type for the esophagus and the wide-opening type used for stiff mucosa.

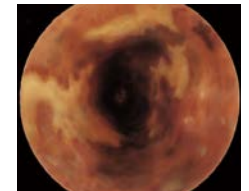


Biopsy forceps with needle

Main diagnostic method

Dye Spraying

In order to identify tumors or other lesions in the early stages, dye, such as Indigo carmine solution and Lugol's iodine solution, is sprayed on the surface of the mucosa. This procedure enables easier observation of mucosal surface shape change.



Spraying Lugol into the esophagus (image)

Main endotherapy device used

Spraying Tube

An endotherapy device for spraying dye on an observation site.



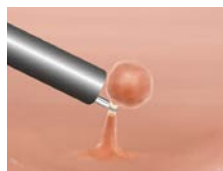Spraying tube

Digestive Tract (Esophagus/Stomach/Colon/Small Bowel)

Method of treatment in internal medicine for **benign polyps**

Polypectomy

A polypectomy is a procedure that removes local elevated lesions called polyps which grow out of the mucous epithelium. A wire snare is looped around the base of the polyp, and a high-frequency electrical current is applied while the snare is tightened. The polyp is then burned off and collected using gripping forceps. There is also a method called "cold polypectomy," in which polyps of less than 10mm are squeezed and removed without applying high-frequency current.

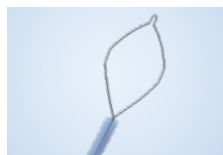

Polypectomy

Main endotherapy device used

Electrosurgical Snare

An electrosurgical snare is an endotherapy device made of looped metal wire. The device applies a high-frequency current to ligate the lesion site and then burn off the lesion. Among high-frequency snares are ones that can carry out a cold polypectomy that severs the lesion without applying a high-frequency current.

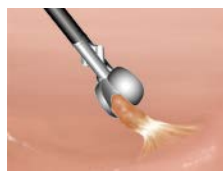

Electrosurgical snare

Method of treatment in internal medicine for **benign polyps**

Hot Biopsy

For small polyps and relatively flat (sessile) polyps, a procedure called a biopsy can be performed. While pinching the polyp with a biopsy forceps, high-frequency current is used to remove the tissue and cauterize the polyp base, preventing bleeding from the site.



Hot biopsy

Main endotherapy device used

Hot Biopsy Forceps

Hot biopsy forceps can collect tissue while applying a high-frequency current to a cup unit. The end section is about the same structure as a biopsy forceps. The operating section has a plug for connecting to an electrosurgical generator.

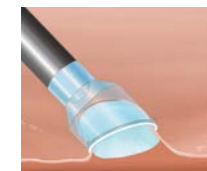

Hot biopsy forceps

Method of treatment in internal medicine for **esophageal cancer, stomach cancer, colorectal cancer, and benign polyps**

Endoscopic Mucosal Resection (EMR)

EMR enables the removal of small flat lesions such as early-stage cancers. There are several techniques for performing EMR. One of these is so-called "cap EMR" (EMRC). This procedure uses a transparent plastic cap fitted over the tip of the endoscope. The lesion is first raised by injecting normal saline into the submucosa under the lesion. The raised tissue is then sucked into the cap attached to the tip of the endoscope and is cut off using an electrosurgical snare positioned inside the cap. The lesion is then recovered using suction.



EMRC method

Main endotherapy device used

Transparent Cap

Equipped with a scope end-section, transparent cap is used to remove a lesion by suction.

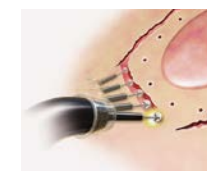


Transparent cap

Method of treatment in internal medicine for **esophageal cancer, stomach cancer, and colorectal cancer**

Endoscopic Submucosal Dissection (ESD)

EMR is limited to removing lesions smaller than 2cm. ESD was developed as a procedure for removing much larger (and more irregularly shaped) lesions. First, an electrosurgical electrode is used to make small burn marks to outline the area around the lesion. The lesion is then raised by injecting normal saline into the submucosa to separate the lesion from the normal tissue below. Next, the mucosa around the lesion is cut using an electrosurgical knife. The submucosa is then separated, and the lesion is recovered using forceps.




ESD

Main endotherapy device used

Electrosurgical Knife

A therapeutic device for removing larger early-stage lesions. There are knives with a ceramic insulator attached to the tip of the needle knife. The insulator lowers the risk of perforation in the digestive tract and also enables large-scale mucosa removal.



Electrosurgical knife

Digestive Tract (Esophagus/Stomach/Colon/Small Bowel)

Main treatment method in internal medicine

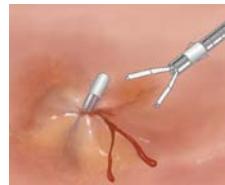Hemostasis

A hemostasis procedure is sometimes required to control the bleeding that results from removing polyps and other lesions. There are several ways to stop bleeding using an endoscope.


Main endotherapy devices used

Clip

The clip acts to pinch the open blood vessel closed, and applies pressure to the tissue to stop the bleeding. In the clip hemostasis method, the clip tip is left in place after compression.



Clip hemostasis



Clip



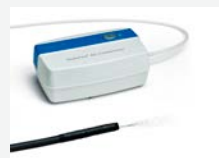High-frequency hemostatic forceps

High-Frequency Hemostatic Forceps

Hemostatic forceps that use high-frequency securely grip large blood vessels or hard and slippery tissue, enabling coagulation to occur.

EndoClot, Hemostasis Solution

EndoClot Polysaccharide Hemostatic System (PHS) is an advanced powder hemostat that is applied during a procedure using consistent air pressure intended to provide more control of delivery. It is indicated for use in combination with other conventional techniques, such as clips, for large and diffuse bleeds, including those occurring in peptic ulcers, post-biopsy, polypectomy, tumor bleeding, post EMR and ESD.



EndoClot PHS

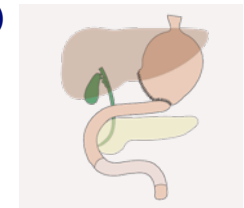
Method of surgical treatment for **stomach cancer**

Laparoscopy-Assisted Distal Gastrectomy (LADG)

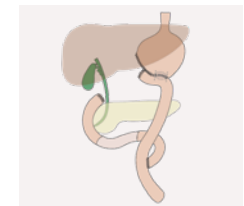
This surgery is limited in application to early-stage cancers from the lower part of the stomach (pyloric antrum) to the middle of the stomach (body of the stomach). The standard procedure is to remove at least two-thirds of the stomach and the lymph nodes around the stomach. The reason this is called a "laparoscopy-assisted" procedure is that the surgery requires a laparotomy, albeit with a smaller incision.

The two basic methods for reconstructing the stomach are the Billroth I method and the Roux-en-Y method. In the Billroth I method, the remaining stomach and the duodenum are joined. In the Roux-en-Y method, the remaining stomach and the jejunum are joined, and the remaining duodenum is connected to the bottom of the jejunum. Food flows from the stomach to the jejunum, where it mixes with digestive fluids that flow in from the duodenum.

If these surgeries are not appropriate for the patient due to tumor location or disease extent, another kind of stomach cancer surgery called Laparoscopy-Assisted Total Gastrectomy (LATG) is performed instead.



Billroth I method

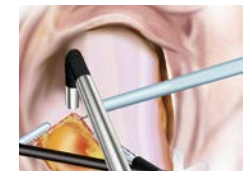

Roux-en-Y method

Method of surgical treatment for **colorectal cancer**

Laparoscopy-Assisted Colectomy

Colorectal cancer surgery involves resection of the affected segment of the colon or rectum, along with removal of the associated regional lymph nodes. Compared with gastric surgery, the vascular and lymphatic anatomy of the colon is relatively consistent and well defined, which makes lymph node dissection well suited to laparoscopic techniques. As a result, laparoscopy-assisted colectomy has become an established standard surgical approach for many patients with colon cancer, offering comparable oncologic outcomes with the benefits of minimally invasive surgery.



Laparoscopy-assisted colectomy

Note:
The above image of the procedure is from the case report by Dr. Arita of Kyoto Prefectural University of Medicine.

Main therapeutic device used

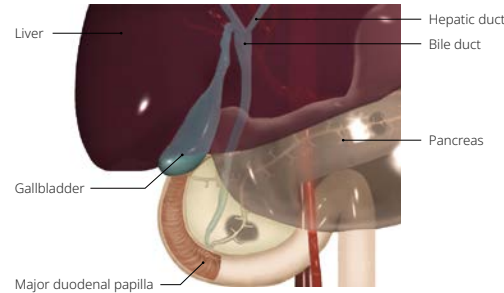
Surgical Systems

Systems used in surgery are described on pages 17-18.

Hepato-Pancreato-Biliary

> Gallstones

A medical condition in which a stone can appear in the biliary tract (generic term for the bile duct, gallbladder, and major duodenal papilla). Gallstones that form in the gallbladder are particularly common. Biliary tract cancers, which can appear in the gallbladder and bile duct, are understood to be connected to gallstones. If gallstones injure the biliary tract, they can cause inflammation, which can turn into cancer if prolonged.



> Pancreatic Cancer

It comes from pancreatic cells. Pancreatic cancer is divided into two types: exocrine (digestive enzyme secretion system) and endocrine (hormone secretion system). About 95% of pancreatic cancer is of the exocrine type, and about 85% of these are invasive pancreatic duct cancers that occur on the epithelium of the pancreatic duct. Pancreatic cancer typically occurs in individuals who are 50–70 years old, especially in elderly males.

Ultrasound Gastrointestinal Videoscope/ Diagnostic Ultrasound System

In addition to standard endoscopy, Endoscopic Ultrasonography (EUS) using medical ultrasound technology is performed to detect lesions that cannot be observed on the surface and are located deep within the organs. These examinations use an ultrasound gastrointestinal videoscope equipped with an ultrasound transducer installed on their tip, together with an ultrasound diagnostic system.

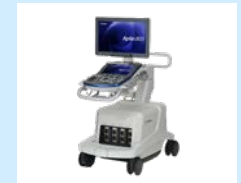In the digestive tract, this kind of endoscope is used to find tumors and cancers hidden below the surface of the GI tract and to examine varices in the esophagus. They are also used to find cancer, gallstones and pancreatic stones in the pancreas and biliary tract. Biopsy needles inserted under ultrasound guidance help diagnose hidden submucosal tumors and contribute to the diagnosis and management of pancreatic cysts.

We began a collaboration on Endoscopic Ultrasound Systems with Canon Medical Systems Corporation (Canon Medical) in 2024. The Aplio i800 diagnostic ultrasound system for EUS, manufactured by Canon Medical, is designed to support advanced EUS procedures with powerful imaging that enhances penetration and resolution and offers an abundance of advanced, clinically validated tools.

Through our collaboration, we will achieve further qualitative improvements in the quality of images and performance in diagnosis and minimally invasive treatment of EUS, ultimately contributing to facilitate the early detection of diseases.



Ultrasound gastrointestinal videoscope



Aplio i800 EUS diagnostic ultrasound system

Duodenoscope

Unlike gastrointestinal videoscopes and colonoscopes, duodenoscopes have a side-viewing tip design in which the lens and illumination optics are on the side of the scope. This enables the scope to perform procedures such as Endoscopic Retrograde Cholangio Pancreatography (ERCP) that is imaging of the pancreaticobiliary ducts via the duodenum, and for performing Endoscopic Sphincterotomy which allows removal of gallstones via the mouth. This endoscope has a prism at its tip to allow it to look perpendicular to its axis, and a forceps elevator to deflect accessory devices in the same direction. Duodenoscopes typically are 1,240mm long.



Duodenovideoscope



Side-viewing tip design (including forceps elevator system)

Note: A single-use scope is planned for future release.

Cholangioscope

Cholangioscope is a miniature scope inserted in the instrument channel of a duodenovideoscope. It can be used for direct observation inside the narrow duct of the pancreaticobiliary system or to collect tissue.



Cholangioscope

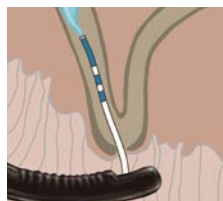Note: A single-use scope is planned for future release.

Hepato-Pancreato-Biliary

Diagnostic method for **gallstones and pancreatic cancer**

Endoscopic Retrograde Cholangiopancreatography (ERCP)

ERCP is method for examining the biliary tract and pancreatic duct using a combination of endoscopic and radiographic techniques. Using an endoscope, a thin tube (cannula) is inserted through the papilla of Vater into a duct of the pancreaticobiliary system. Radiological contrast dye is then injected into the ducts, and the area is viewed using X-rays.

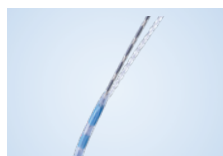

ERCP

Main endotherapy device used

Cannula

A thin tube for injecting radiological contrast dye into the pancreatic or bile duct that can then be viewed by X-rays.

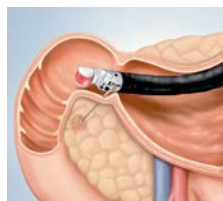

Cannula

Diagnostic method for **pancreatic cancer**

Endoscopic Ultrasound-Guided Fine Needle Biopsy (EUS-FNB)

EUS-FNB is an examination technique that combines ultrasound and endoscopy technologies, enabling physicians to obtain tissue or cell biopsies of lesions from areas such as the pancreas that cannot be accessed directly by the endoscope. For example, a needle biopsy may be performed through the wall of the gastrointestinal tract with the ultrasound scope being inserted orally and ultrasound imaging used for sub-mucosal visualization. Collected tissue samples are then sent for pathological evaluation to determine whether the lesion is benign or malignant.



EUS-FNB

Main endotherapy device used

EUS-FNB Needle

This endotherapy device is designed for use with an ultrasound endoscope to obtain tissue or cell biopsies from lesions in areas such as the pancreas.

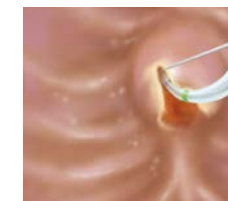

EUS needle

Method of treatment in internal medicine for **gallstones**

Endoscopic Sphincterotomy

It is a procedure that is often used to remove gallstones. A papillotomy knife (papillotome) is inserted into the opening of the duodenal papilla, and the papillary sphincter is cut open. Following this, a stone extraction balloon or stone retrieval basket can be inserted into the biliary ducts to remove any gallstones residing in the biliary system.



EST

Main endotherapy devices used

Papillotome

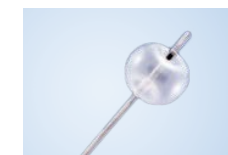An electrosurgical knife inserted into the papilla at the end of the bile duct for use in incision using high frequencies.



Papillotome

Stone Extraction Balloon

A balloon-shaped catheter used to scrape out small stones resembling sand and silt.



Stone extraction balloon

Stone Retrieval Basket

An endotherapy device that is used to help retrieve and remove stone fragments from the bile duct.



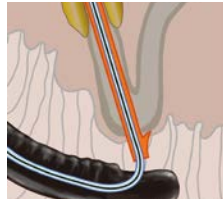
Stone retrieval basket

Hepato-Pancreato-Biliary

Method of treatment in internal medicine for **gallstones**

Endoscopic Biliary Drainage (EBD)

If the free flow of bile to the duodenum is hindered due to gallstones or a stricture (narrowing) of the bile duct due to disease, EBD may be performed by inserting a plastic or metal stent into the duct to allow the free flow of bile.



EBD

Main endotherapy devices used

Plastic Stent

When a bile duct has a stricture or blockage, this stent is inserted into the duct and releases bile. The device is implanted for a short period of time (around several weeks).



Plastic stent

Metal Stent

This stent is made of metal mesh. The post-implantation lumen is larger than for a plastic stent and can be expected to have large drainage. Comparatively long-term (around several months) patency and detainment is possible.

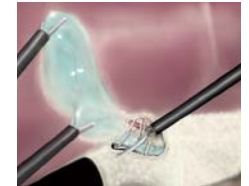


Metal stent

Method of surgical treatment for **gallstones**

Laparoscopic Cholecystectomy

The gallbladder is located on the undersurface of the liver. During laparoscopic cholecystectomy, the surgeon carefully dissects the structures within Calot's triangle to obtain the critical view of safety and clearly identify the cystic duct and cystic artery. These structures are then secured with surgical clips and divided. The gallbladder is subsequently dissected from the liver bed using an electro-surgical device, with traction provided by grasping forceps. Once completely freed, the gallbladder is placed in a retrieval bag and removed from the abdominal cavity through one of the trocar sites.

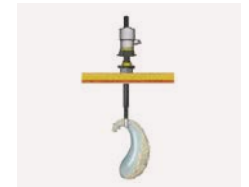

Detachment of gallbladder

Main therapeutic device used

Surgical Systems

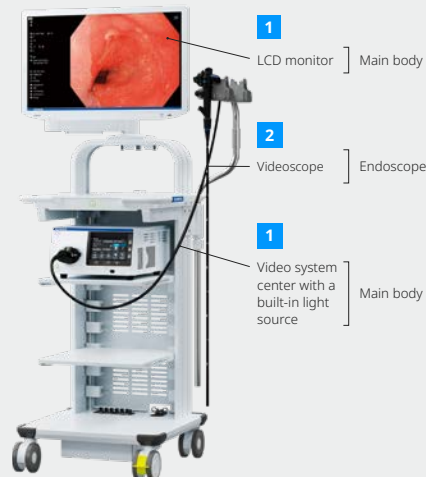
ii Systems used in surgery are described on pages 17-18.



Removal through incision

1 Main Body: LCD Monitor, Video System Center

The video system center converts the electrical signals from an image sensor at the tip of a videoscope into video signals and displays them on an LCD monitor. In addition to high-definition vision, the system supports various types of image processing including color enhancement and Narrow Band Imaging (NBI). The latest units are integrated with a light source and come equipped with an LED with a long life span. To improve color reproductivity, the system has adopted five-color LEDs supporting violet, blue, green, amber, and red. It also has an automatic dimming feature (automatically adjusts the brightness) and a pump that transmits water and air.



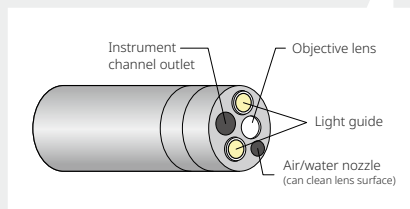
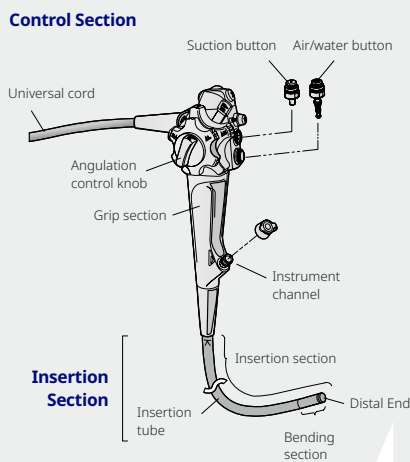
2 Endoscope

The endoscope consists of three parts: the control section, the insertion section, and the connector section.

Control Section

The angulation knob on the control section is connected to the tip of the endoscope by a series of wires. By turning the angulation knob, the bending section at the distal end bends horizontally and vertically allowing for easier insertion into the body and the ability to view 360 degrees within body cavities.

The endoscope also contains buttons (valves) for feeding air or water and for applying suction. Covering the opening in the air/water valve will feed air into the organ being observed and will gently expand it for a better view. Depressing this valve will feed water through the endoscope to wash the viewing lens. Depressing the suction valve will allow the doctor to use the endoscope to suction any fluids which are obscuring a good view of the tissue. Endotherapy devices can be passed through the instrument channel for performing endoscopic biopsy and other treatments.



Insertion Section

On the tip of the insertion section, there are four main parts: 1. Objective lens and image sensor, 2. Light guides that bring light from the light source through the endoscope, 3. Instrument channel outlet where endotherapy devices can be pushed in and out (also has a suction opening), 4. Nozzle for feeding water and air.

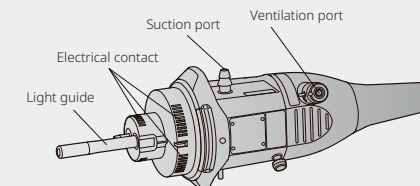
The objective lens is typically a super-wide-angle lens in order to visualize a large area of tissue at one time. In order to view tumor tissue in a more detailed manner, some endoscopes have an optical zoom feature. They also support high-definition video displays.

Light guide fiber bundles conduct light from the external light source through the endoscope to illuminate body cavities. Endotherapy devices are pushed in and out of the instrument channel for harvesting tissue (biopsy), removing tumors, cauterizing bleeding lesions, etc. The nozzle on the distal tip is used to clean the lens with water and expand body cavities by insufflating them with air.

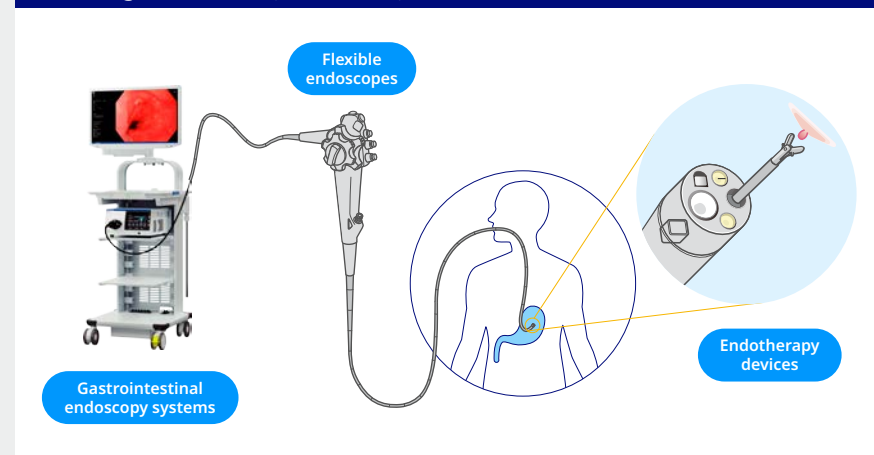
Connector Section

The connector section connects the endoscope with the video system center through the universal cord. Supply of air and water is also performed through this connection.

Connector Section

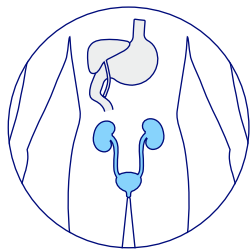


Main Usage Scenes (Examples of Endoscopic Examination)



Urology

Endoscopic evaluation of the genitourinary tract for diagnosis, staging, surveillance, and treatment of benign and malignant diseases



Scopes



Urology videoscope



Rigid cystoscope




Resectoscope

Therapeutic devices



Plasma resection for BPH and NMIBC*



Minimally invasive treatment device for BPH

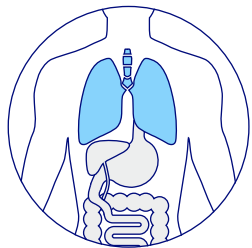


Thulium fiber laser system

*Non-muscle-invasive bladder cancer

Respiratory

Endoscopic evaluation of the tracheobronchial tree for observation, diagnosis, staging, and treatment of benign and malignant diseases



Scopes



Bronchoscope

Endotherapy devices

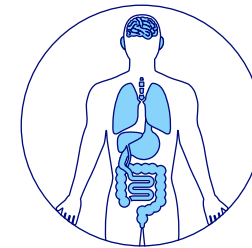


Aspiration needle



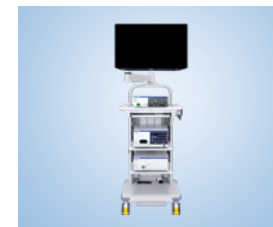Endobronchial valve

Surgical



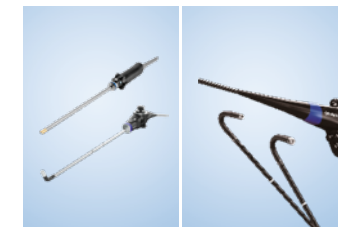The surgical endoscope is inserted through a small hole into body cavities (abdomen and thorax) for laparoscopic surgical procedures.

Surgical endoscopy systems



Surgical endoscopy systems

Surgical endoscopes



Laparoscope/Thoracoscope

Flexible rhino-laryngoscope

Surgical energy devices

Enabling laparoscopic and open surgical procedures by providing tissue grasping, manipulation, dissection, coagulation, and vascular control.



Surgical energy platform and devices

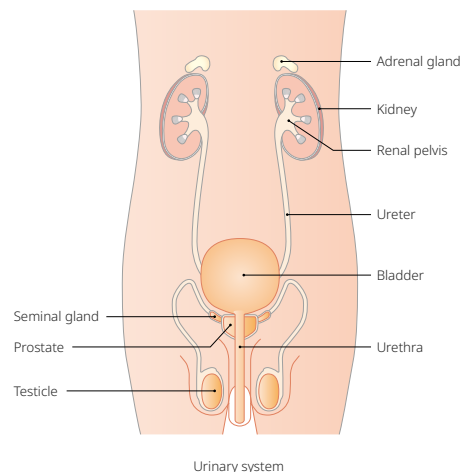
Urology

> Benign Prostate Hyperplasia (BPH)

A condition in which urination is obstructed by the enlarged prostate blocking the outflow of the bladder. Symptoms include a sensation of residual urine and more frequent trips to the toilet due to the reduced amount of urine passed at each urination.

> Urinary Stone

A condition in which substances contained in urine crystallize for some reason and coalesce in the form of a stone. Typical symptoms include extreme pain, bloody urine, or the presence of the stone in urine.



> Bladder Tumor (Bladder Cancer)


This occurs when the lining of the bladder (urothelium) develops a cancerous growth. While most cases (90% or more) are categorized as urothelial cancer, rare instances of squamous cell carcinoma and adenocarcinoma also occur. The main symptoms are bloody urine or pain during urination.

Ureteroscope/Cystoscope

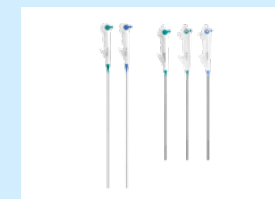They are used for viewing the urinary bladder through the urethra and the kidneys through the urinary duct. Olympus manufactures both videoscopes and fiberscopes for this application. The videoscope version supports high-definition imaging due to its high performance imager and is also capable of NBI. Moreover, in order to facilitate the observation of the bladder neck, both the Up and Down sides bending angle of 275 degrees are realized.



Reusable urology videoscope



Flexible bending function



Single-use urology videoscope

Note: A single-use urology videoscope is available in selected countries.

Resectoscope

A resectoscope is a rigid endoscope for diagnosing and treating the urethra and bladder. It is inserted in from the external urethral orifice and used for the surgical resection of a lesion with high-frequency current.



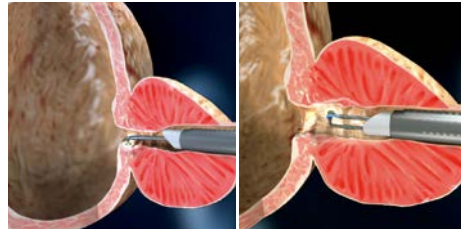Resectoscope

Urology

Method of treatment for **BPH and bladder tumors (bladder cancer)**

Transurethral Resection (TUR)

TUR is a procedure in which a surgeon inserts a resectoscope from the urethra and then, using the handle, operates a loop-shaped electrode to surgically resect tissue from an enlarged prostate or a bladder tumor with an electro-surgical knife. For a safe procedure and precise resection, the solution from Olympus is the TUR is procedure, in which a resection is performed by discharging electricity from the entire area surrounding the electrode through saline.



Resection of the enlarged prostate when a resectoscope is inserted transurethraly near the neck of the urinary bladder

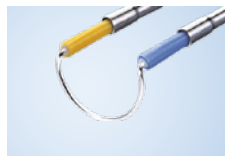Main therapeutic device used

Electrosurgical Generator

The equipment enables incision of a lesion and coagulation by connecting to an endotherapy device and generating a high-frequency current.



Electrosurgical Generator



Resectoscope and special-use electrode

Method of treatment for **BPH**

Treatment through Non-Ablative Device

Olympus is rolling out iTind, a minimally invasive treatment device that ensures urine flow by reshaping the bladder neck and prostatic urethra over the span of five to seven days after longitudinally implanting a three-wire nitinol device in the prostate. iTind enables a patient to be treated at a doctor's office or clinic, returning home the same day, and to achieve resolution of symptoms without a permanent implant left behind.



Minimally invasive treatment device for BPH

Method of treatment for **urinary stones**

Transurethral Lithotripsy (TUL)

During Lithotripsy, an urologist navigates an endoscope through the urinary tract and uses laser or ultrasonic energy to break up one or more stones in the bladder, ureter, or kidney. The resulting stone fragments may be expelled naturally or can be removed through a ureteral sheath or using stone retrieval baskets.

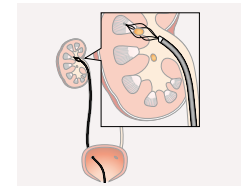


Image of removing stones with stone retrieval baskets

Main therapeutic device used

Thulium Fiber Laser System

This product uses superpulsed thulium fiber laser technology for the removal of stones in the urinary tract (the kidney, ureter, bladder, and urethra) and for resection of soft tissue. It works by breaking up the stone into tiny pieces which are then passed out of the body during urination. The device helps shorten operation time by improving performance for breaking the stones. The device is also used to treat soft tissue (such as the prostate), enabling Olympus to provide urologists with a variety of procedural solutions. The compact size of the equipment helps to save space and make movement easier between operating rooms.



Thulium fiber laser system

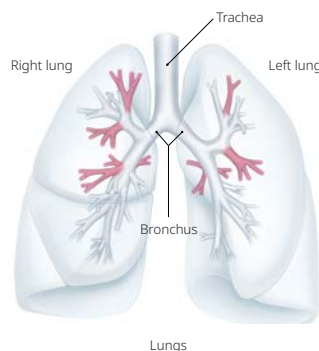
Respiratory

> Lung Cancer

Lung cancer consists of malignant tumors of the bronchial tubes and pulmonary epithelium. Instances are on the rise due to smoking and other causes. Lung cancer is the most common cause of cancer death worldwide*1.

> Benign Pulmonary Disease (COPD)

Refers to a group of diseases caused by inflammation or impaired function of the lungs and airways, rather than malignant tumors such as cancer. A representative example is chronic obstructive pulmonary disease (COPD), which includes emphysema, a disease in which the alveoli at the ends of the bronchi become enlarged and lose their function. Inhalation of harmful substances such as tobacco can cause inflammation of the lungs and bronchi, which leads to progressive shortness of breath.



Bronchoscope

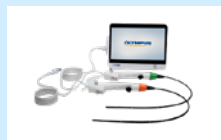Olympus reusable bronchoscope portfolio is designed for use in the diagnosis and treatment of respiratory conditions. The portfolio incorporates high-resolution imaging and ergonomic designs intended to support visualization of the central, segmental, and subsegmental airways. These bronchoscopes are used across diagnostic and therapeutic procedures to support procedural efficiency and clinical workflow.

The Olympus single-use bronchoscope portfolio offers a range of bronchoscope sizes and features intended to address varied clinical scenarios and patient needs. Single-use availability enables on-demand access and may complement reusable bronchoscopy programs by offering flexibility in scope selection and workflow across care settings.

Note: Single-use bronchoscope is available in the U.S. and selected European countries.



Bronchoscope



Single-use bronchoscopes and processor

EBUS Bronchoscope

This scope is equipped with an ultrasonic transducer (probe) at its tip and is used when performing endobronchial ultrasound-guided transbronchial needle aspiration (EBUS-TBNA). With a small outer diameter and a wider angulation range, the peripheral EBUS bronchoscope extends EBUS-TBNA-guided tissue sampling for both lesion diagnosis and lymph-node staging in the peripheral zone that were not previously accessible by traditional EBUS bronchoscopes*2.

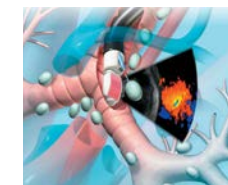


Peripheral EBUS bronchoscope

Diagnostic method for lung cancer

Endobronchial Ultrasound-Guided Transbronchial Needle Aspiration (EBUS-TBNA)

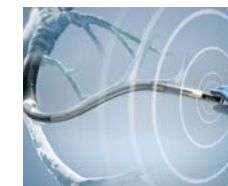A technique mainly for the purpose of diagnosing enlarged lymph nodes in lung cancer, inflammatory or infectious diseases. The procedure uses ultrasonic images in real time to guide the insertion of a needle into the lymph node via the trachea and bronchus for the collection by aspiration of cell or tissue samples. The collected samples are observed and diagnosed in detail by pathological examinations before deciding on the next course of treatment.



EBUS-TBNA system

Radial EBUS

A technique used to localize small lung lesions to biopsy. Ultrasonic images guide a catheter or peripheral bronchoscope to find nodules outside of the airways. Most commonly looking for early stage lung cancer to diagnose it when it has not spread to lymph nodes.



Radial EBUS

*1 WHO cancer statistics: <http://www.who.int/news-room/fact-sheets/detail/cancer>

*2 Takashima Y, Shinagawa N, Shoji T, et al. Evaluating the Efficacy of Thin Convex-probe Endobronchial Ultrasound Bronchoscope in Cadaveric Models. J Bronchology Interv Pulmonol. 2025;32(3):e01015. Published 2025 May 21. doi:10.1097/LBR.0000000000001015

Respiratory

Main endotherapy device used

Aspiration Needle

This endotherapy device is designed for use with an ultrasound bronchoscope and enables the collection of cell or tissue samples from the trachea and bronchi through aspiration.

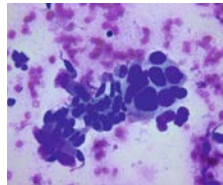


EBUS bronchoscope and aspiration needle

Diagnostic method for lung cancer

Cytology

Cytology is performed by observing collected cells under a microscope to detect malignant features consistent with lung cancer.

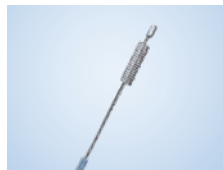

Cytology image of lung cancer cells

Example endotherapy device used

Cytology Brush

A brush for collecting cells from the bronchial tubes with narrow openings. The cytology brushes are 1-5mm in diameter and less than 10mm in length.

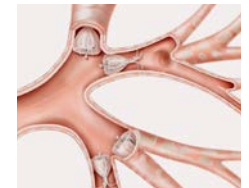

Cytology brush

Method of treatment for benign pulmonary disease (COPD)

Bronchoscopic Lung Volume Reduction

A minimally invasive procedure for severe emphysema. The procedure reduces lung volume by deploying a valve within the bronchial airway to block airflow to the diseased portion of the lung. Specifically, a small, umbrella-shaped valve is implanted in the lung's upper lobe bronchus via a catheter inserted into the instrument channel of a bronchoscope. The purpose is to redirect the airflow from the unhealthy part of the lung to the normal/healthy section.



Intrabronchial valve system

Main endotherapy device used

Endobronchial Valve

This valve is a therapeutic device for severe emphysema. It is used when medicines have no effect or in which neither a lung reduction procedure nor transplant surgery is not applicable. It is also used to treat postoperative prolonged air leaks arising from a pneumothorax or lung surgery.

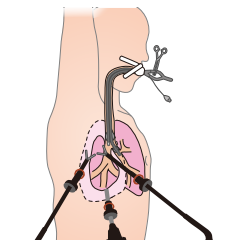


Endobronchial valve

Method of treatment for lung cancer

Pulmonary Resection

Lung cancers are now being surgically resected using endoscopes. Thoracoscopic partial lung resection surgery can be performed for removing tumors smaller than 3cm in diameter, and lung lobectomies performed for treating areas greater than 4cm in breadth.



Pulmonary resection (image)

Main therapeutic device used

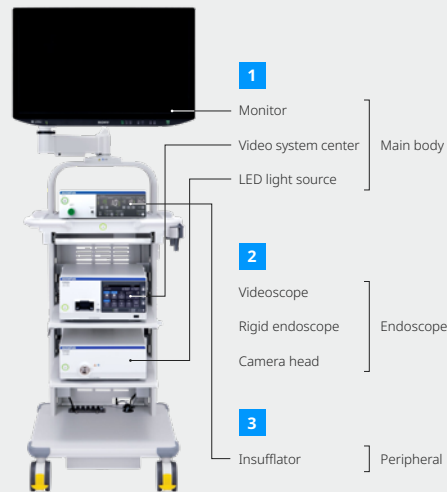
Surgical Systems

Systems used in surgery are described on pages 17-18.

1 Main Body: Monitor, Video System Center, LED Light Source

The surgical endoscopy system includes models that support 3D scopes, which help surgeons perceive depth more easily; models that provide high-resolution 4K images for clearer visualization of fine details; models that enable IR imaging; and models that have multiple combinations of these functions in a single system.

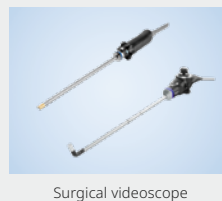The video system center acts as the core processor of the system. It converts electrical signals from the videoscope or camera head into video signals and displays them on a monitor. The light source delivers light through a light-guide cable to the tip of the scope, illuminating the inside of the body during procedures.



2 Endoscope

Surgical Videoscope

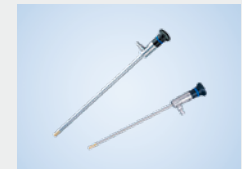General laparoscopic and thoracoscopic videoscopes have a diameter of approximately 5–10mm and a length of 300–370mm. At the tip of the slim metal tube, a lens, image sensor, and light guide are integrated. Some scopes have a flexible (articulating) tip, while others are straight. Because they have a deep depth of field, manual focus adjustment is generally not required.



Rigid Endoscope (Telescope) and Camera Head

By connecting a rigid endoscope, which consists of multiple lenses, with a camera head that contains an image sensor, the image can be displayed on a monitor via the video system. This combination of a rigid endoscope and camera head is used not only in laparoscopic and thoracoscopic surgery, but also across a wide range of medical specialties.

For example, in urology it is used for procedures such as transurethral prostate resection. In ENT, thin rigid endoscopes are used to observe, diagnose, and treat areas such as the eardrum, nasal sinuses, and vocal cords. In gynecology, they are used for procedures including fibroid removal and polyp resection, while in orthopedics they are used for treatments inside joints.

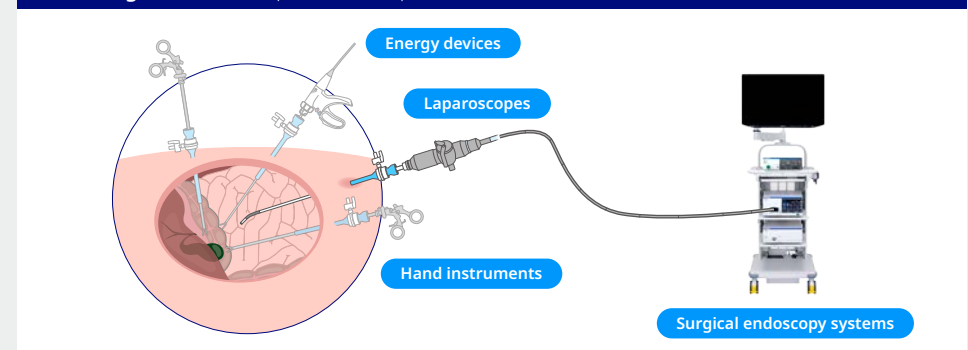


3 Peripheral

Insufflator

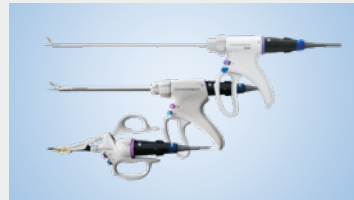The insufflator feeds carbon dioxide gas into the abdominal cavity in order to expand it and create a working space to perform surgery. A special insufflation needle (Veress needle) delivers the carbon dioxide gas to the peritoneal cavity. The insufflator monitors the pressure of the peritoneal cavity and automatically pumps in additional gas as needed to make up for gas that naturally leaks out during surgery.

Main Usage Scenes (Examples of Endoscopic Examination)



Hybrid Energy Devices

Surgical energy devices are used to cut tissue and control bleeding during laparoscopic and open procedures. Hybrid energy devices combine the advantages of ultrasonic and advanced bipolar energies to deliver fast tissue cutting and strong blood vessel sealing.



Hybrid energy devices

Laparoscopic Hand Instruments

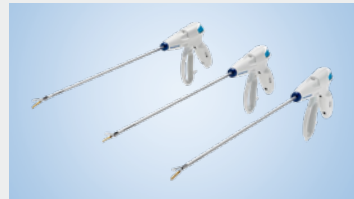Reusable monopolar and bipolar laparoscopic instruments such as scissors, electrodes, needle holders and suction/irrigation devices assist surgeons in managing a broad range of tissue conditions during laparoscopic procedures.



Laparoscopic hand instruments

Advanced Bipolar Devices

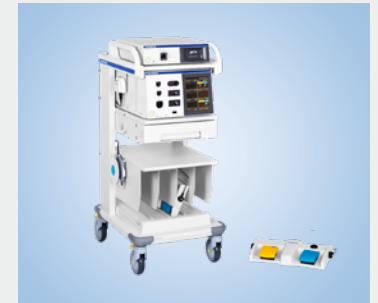Advanced bipolar energy devices are used to control bleeding and cut through soft tissue during laparoscopic and open procedures. Different jaw configurations support various surgical techniques.



Advanced bipolar devices

Surgical Energy Platform

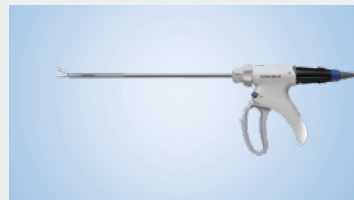This versatile generator system enables hybrid, advanced bipolar and ultrasonic devices, together with standard electro-surgical instruments, to deliver standardization across operating rooms.



Surgical energy platform

Ultrasonic Energy Devices

Ultrasonic devices convert electricity into ultrasonic vibrations, enabling fast, efficient tissue cutting during laparoscopic and open procedures.



Ultrasonic energy device

OLYMPUS
